

Article

Laser Removal of Cosmetic Eyebrow Tattoos with a Picosecond Laser

Candice Menozzi-Smarrito *  and Stéphane Smarrito

Riviera Clinic, Quai Perdonnet 3, 1800 Vevey, Switzerland

* Correspondence: direction@riviera-clinic.ch

Abstract: This current retrospective study, including 98 patients aged 21 to 71 years, aims to assess the safety and the efficiency of a picosecond 755 nm/532 nm laser in the removal of complex eyebrows tattoos. Patients were treated with a picosecond laser at 755 nm with fluences ranging from 0.69 to 6.37 J/cm² and at 532 nm with a fluence of 0.64 or 1.12 J/cm². Analyses of Variance (ANOVA, single factor) and comparison tests (F-test) were conducted. A total of 70 subjects finished the full treatment. An average of three laser sessions were necessary to achieve the patients' objective (total removal, attenuation for redo, or correction). The number of sessions was significantly higher if cosmetic tattoos contained visible warm pigments (red, orange, yellow). A total of 18 patients experienced immediate grey discoloration, although this was not found to significantly influence the number of laser sessions. The main side effects were redness, swelling, and bleeding points. One patient experienced a bruise immediately after laser shots. This retrospective study has shown the picosecond laser to be safe and efficient in removing complex cosmetic tattoos. Further investigation is ongoing to assess optimal parameters for treating red and white pigments.

Keywords: picosecond laser; tattoo; lasers and light sources



Citation: Menozzi-Smarrito, C.; Smarrito, S. Laser Removal of Cosmetic Eyebrow Tattoos with a Picosecond Laser. *Dermato* **2023**, *3*, 182–192. <https://doi.org/10.3390/dermato3030014>

Academic Editor: Hei Sung Kim

Received: 27 March 2023

Revised: 13 June 2023

Accepted: 16 June 2023

Published: 3 July 2023



Copyright: © 2023 by the authors. Licensee MDPI, Basel, Switzerland. This article is an open access article distributed under the terms and conditions of the Creative Commons Attribution (CC BY) license (<https://creativecommons.org/licenses/by/4.0/>).

1. Introduction

The use of permanent and semi-permanent eyebrow makeup has increased considerably in recent years. First developed in the United States more than 20 years ago, it is now practiced widely throughout the world. Several techniques have been developed to meet the growing demand for stable and personalized results. We can distinguish traditional dermopigmentation with a tattoo gun, microblading, or brow-shading techniques according to method and duration [1].

Whatever the dermopigmentation technique used, the cosmetic tattoo ink for eyebrows is generally a complex mixture of pigments. They may contain mineral pigments such as red ferric iron oxide (Fe₂O₃, CI 77491), yellow hydrated ferric iron oxide (Fe₂O₃·H₂O, CI 77492), black ferrous iron oxide (Fe₃O₄, CI 77499), green chromium oxide (Cr₂O₃, CI 77288), or white titanium oxide (TiO₂, CI 77891). Organic pigments are also included in ink formulations, the simplest being carbon black. Azo derivatives, which are among the most widely used classes of organic pigments in cosmetic tattoos, provide red, orange, and yellow colors [2]. Given the chemical complexity of cosmetic tattoo inks, the removal of eyebrow tattoos remains challenging.

Treatment options for tattoo removal are multiple, but some of them show significant limitations since they do not specifically target the tattoo pigments but rather the tissues in which the pigments are located [3]. Thus, the procedures like dermabrasion (skin resurfacing), chemical removal via caustic products (e.g., lactic acid, salicylic acid, and phenol), or the use of electromagnetic waves are associated with adverse effects such as scar and definitive dyschromia [3–6].

Laser treatment is the gold standard for tattoo removal [7–11]. Nanosecond (NS) Q-Switched Alexandrite (755 nm) and Neodymium-doped Yttrium Aluminum Garnet

lasers (1064 nm) have been used to remove cosmetic eyebrow tattoos with limited side effects [12–18]. Cannarozzo et al. reported the successful use of a nanosecond Q-switched Nd:YAG laser on 20 patients to remove cosmetic tattoos on the lips, eyebrows, and eyelids [18]. A retrospective study conducted on 40 patients also showed that NS Nd:YAG laser provided good clearance of blue-black Chinese eyeliner tattoos [12]. Moreover, black and red-brown cosmetic tattoos on eyebrows were, respectively, treated using NS Alexandrite (755 nm) and Nd:YAG lasers to achieve a complete clearance after five treatments with no scars, pigmentary alterations, or textural changes [15,16].

Picosecond (PS) lasers have recently emerged as a promising technology for tattoo removal [8,19–21]. Their very short pulse lengths in the picosecond domain, which is close to the thermal relaxation time of pigment particles, make it possible to efficiently increase their photomechanical breakup [22]. A 532/1064 nm picosecond Nd:YAG laser was safely used to eliminate brown and black eyebrow tattoos on four patients with skin types (III–IV) in a pilot study [23]. Additionally, when Leu et al. compared PS and NS Nd:YAG lasers for the removal of cosmetic tattoos in rat models, the picosecond laser was found to be superior to the NS laser for removing flesh-colored tattoos [7]. More recently, in the retrospective study conducted by Hartman et al., the use of picosecond 1064 nm laser to remove facial cosmetic tattoos led to satisfactory results after three laser sessions (100 to 50% clearance) [10].

The objective of this study was to investigate the efficiency and safety of a 755/532 nm picosecond laser for the removal of eyebrow tattoos.

2. Materials and Methods

2.1. Design Study

This study involved 98 patients aged 21 to 71 years who visited our center between April 2020 and November 2021 for treatment of cosmetic eyebrow tattoos. Fitzpatrick skin phototypes I to VI were represented. Exclusion criteria included hypersensitivity to light exposure and a history of cell carcinoma or melanoma. Also excluded were pregnant or breastfeeding women. Additionally, patients who are still receiving treatment in our center were removed from the current panel.

Prior to the initial laser treatment, a 30 min consultation was carried out to ascertain their medical history and explain the procedure. We asked each patient if they had ever had an eyebrow tattoo removal (with laser or other methods). Additionally, subjects were asked to define their objective: totally remove their cosmetic eyebrow tattoo, correct it, or attenuate it to redo a new one. Detailed information on eyebrow cosmetic tattoos was collected during the consultation, such as the types of cosmetic tattoos, when the first and last touch ups were performed, and the occurrence of red, yellow, or white pigments. The ink composition was not known in most cases. A visual assessment was then carried out after each laser treatment in order to report any grey discoloration (immediately after the session). Patients were systematically called 24 h after treatment to collect data on any side effects. Photos were taken before each session.

2.2. Laser Treatments of Cosmetic Eyebrow Tattoos

Written informed consent was obtained from all patients prior to the first session. This consent form included authorization to carry out the treatment as well as use photos taken during the sessions. Treatments were performed with a Picosure laser (Cynosure, Westford, MA, USA) at 755 nm using fluences of 0.69–6.37 J/cm² or at 532 nm with fluences of 0.64 or 1.12 J/cm² and a pulsation length of 650 picoseconds. Laser parameters were selected based on patient skin type, color pigments, and clinical endpoint (whitening). The wavelength of 755 nm was first privileged, whatever the pigment color (Figure 1). For example, laser parameters started at 755 nm with 0.76 J/cm² for a skin phototype VI, at 755 nm with 1.13 J/cm² for a phototype V, at 755 nm with 1.31 J/cm² for phototype IV, 755 nm and 1.38 J/cm² for a phototype III and 755 nm with a fluence of 1.45 J/cm² for phototypes II and I. The laser parameters were adapted to each new session, with fluence

increasing as the cosmetic tattoo was lightened. In cases of visible orange, yellow or red pigments and if whitening was not observed at 755 nm (spot test), the wavelength was immediately changed to 532 nm, and a fluence of 0.64 or 1.12 J/cm² was applied.

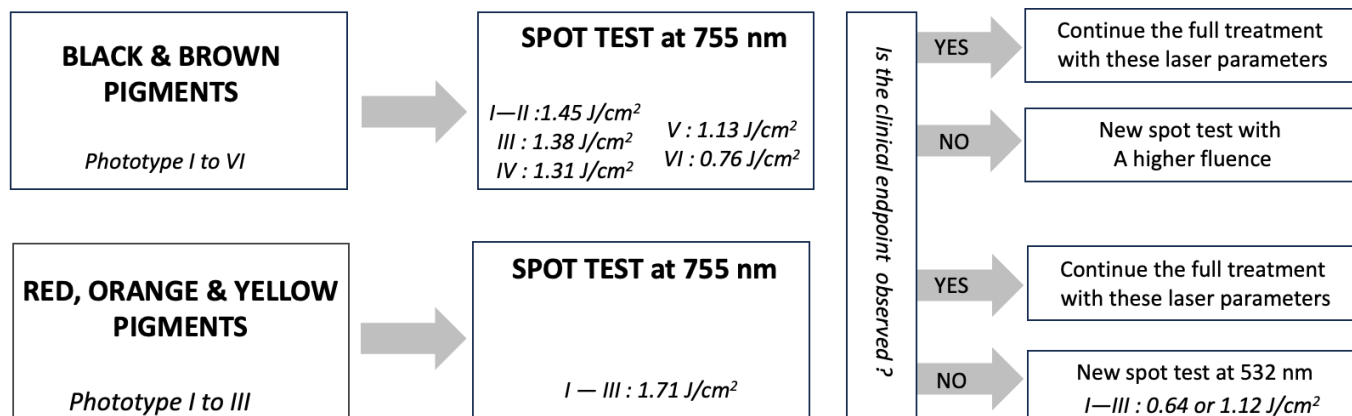


Figure 1. Flowchart summarizing the selection of laser parameters.

Protective eyewear was worn by both the patient and the physician. Patients received treatments with intervals of 4 weeks when treated at 755 nm and intervals of 8 weeks when 532 nm was used as the wavelength.

2.3. Statistical Analysis

Analyses of Variance (ANOVA, single factor) were conducted with Excel software using data from the 70 patients who completed their laser treatment. When $p < 0.05$, differences were considered significant, and additional comparison tests (F -tests) were carried out.

3. Results

3.1. Design Study

The current retrospective study included 97 women and 1 man who came to our clinical center for laser treatment of eyebrow cosmetic tattoos (Table 1). All age groups and phototypes I to VI were represented. The subjects predominantly consisted of women aged 26 to 35 years old. More than 70% of the cases were Fitzpatrick phototype II and III. A total of 22 of the 98 patients had previously undergone treatments in other medical or aesthetic centers, such as dermabrasion (one patient), chemical tattoo removal (15 patients), and laser treatments (10 patients). Three subjects displayed scars or dyschromia prior to treatment in our center due to previous acid-based removal procedures. We observed that these previous experiences of cosmetic tattoo removal had no refractory effect on the following treatments carried out in our medical center.

Of 98 patients who consulted us for the removal of eyebrow tattoos, 5 decided to stop treatment in our center because of the price (3 patients) or dissatisfaction with results (2 patients after, respectively, one and three sessions). Contact was lost with 16 people despite several attempts to contact them (on the phone and email), and we did not know if the treatment was considered complete. There were three patients who were satisfied with the results but decided to continue laser treatments in other centers equipped with Picosure laser (because these were located closer to them). Three patients put their sessions on hold because of pregnancies. The treatment was stopped for one subject due to hyperpigmentation after the second laser session.

Table 1. Demographics and patient history.

Patients	Number
Total	98
Gender:	
Women	97
Men	1
Age:	
18–25	11
26–35	48
36–45	24
46–55	7
>55	8
Phototypes:	
I	5
II	31
III	38
IV	20
V	3
VI	1
Previous experience in cosmetic tattoo removal	22

3.2. Patient Profiles

Using the collected data, patients were classified into four different categories (Figure 1):

- Type I: Permanent make-up Enthusiast patients (PMU-E) who were aware of new trends in permanent make-up and wanted to freshen up their cosmetic eyebrow tattoos. The objective of their laser treatment was to attenuate the existing tattoo to create a new one. Their commitment was intermediate, with 70% of patients completing the full procedure in our center (20% had undergone previous removal treatments).
- Type II: PMU Disappointed patients (PMU-D) who were dissatisfied with their current cosmetic eyebrow tattoos and wanted to completely remove them. They showed a strong commitment, with 94% finishing treatment.
- Type III: PMU Perfectionist patients (PMU-P) who were typically women who considered laser treatment to correct their current eyebrow tattoos (head, tail, or thickness). They showed a high level of commitment, with 92% finishing the full laser treatment.
- Type IV: Uncertain patients (PMU-U) who were certain that something had to be done with their current eyebrow tattoo but were uncertain at the outset of treatment if they wanted to completely remove or redo it. This indecision was reflected in the low rate of commitment, with 50% completing treatment and 22% who had previous at least one tattoo removal experience in other centers.

As Figure 2 shows, PMU Enthusiast, accounting for 37.5% of our panel, was the most important category. PMU Disappointed and Uncertain patients were of similar size (representing 23.75% and 22.5%, respectively), while 16.25% were Perfectionist patients. Interestingly, the differences between categories were discovered in patient age: PMU Disappointed patients were younger than PMU Uncertain ones (average age of 30.5 years vs. 44.6 years).

3.3. Treatment of Cosmetic Eyebrow Tattoos

As Table 2 shows, the patients considered laser treatment in order to totally remove their cosmetic eyebrow tattoo, to correct it (i.e., excessively thick makeup, attenuation of dark or red pigments), or to redo a new one. The eyebrow cosmetic tattoos were permanent make-up (PMU) performed with a tattoo gun, microblading, and brow-shading techniques. In some cases, multiple types of cosmetic tattoos were combined. The cosmetic eyebrow tattoos ranged in age from recent to several years old. In the group of 70 patients who

completed their treatment, the number of sessions ranged from 1 to 8. Warm pigments (red, orange, and yellow) were visible in 42 tattoos, and grey discoloration of warm pigments was observed in 18 patients during their treatment.

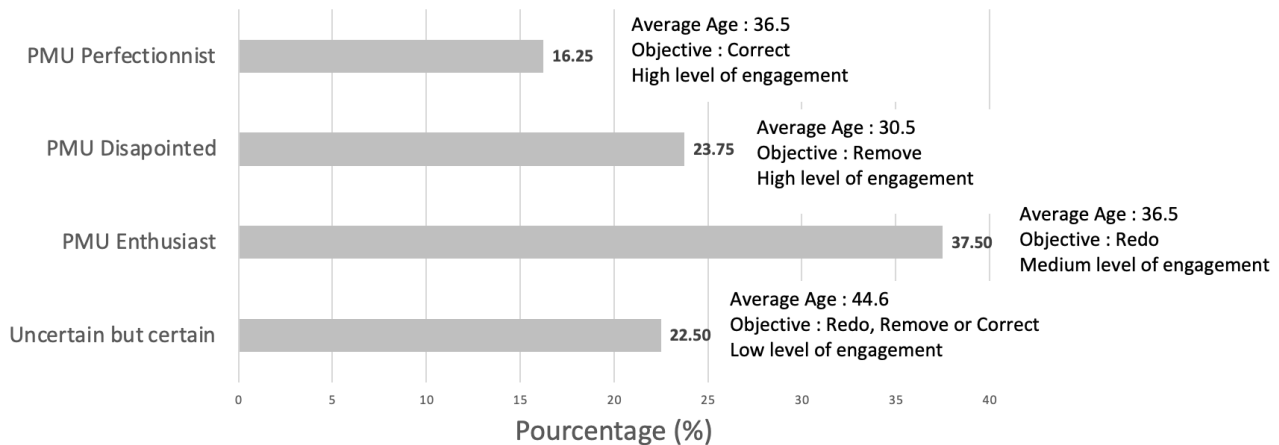


Figure 2. Patients' repartition according to four different categories: PMU Perfectionnist, PMU Disappointed, PMU Enthusiast, and Uncertain patients.

Table 2. Characteristics of cosmetic eyebrow tattoos successfully treated with PS laser. Only subjects who finished their treatment were included.

Cosmetic Tattoos	Number
Total	70
Objective:	
Redo	29
Remove	27
Correct	14
Age of last touch-up:	
<3 months	4
3–12 months	11
1–4 years	32
>4 years	23
Visible warm pigments *	42
Grey discoloration during laser treatment	18
Number of laser sessions	
Average	3
Min	1
Max	8

* Red, orange, and yellow pigments.

Immediate side effects were redness (very frequent), swelling (frequent), the occurrence of bleeding points, bruises (rare), and color change. Figure 3A shows typical grey discoloration of an orange pigment after laser shots at 755 nm. Mild and transient localized erythema generally appeared immediately following the laser session (Figure 3B). Reversible hair discoloration was also observed. No hair loss was reported. One patient experienced bruises immediately after laser shots (Figure 3C). In the days following the laser sessions, the main side effects were sensitized skin (1–3 days), swelling, redness (1–4 days), and rarely crusts. Hyperpigmentation trouble was observed for one patient with phototype V. Itching for a few days after the session was reported for two patients (antiallergic medication was required for one patient). No permanent side effects, such as scars, were observed.

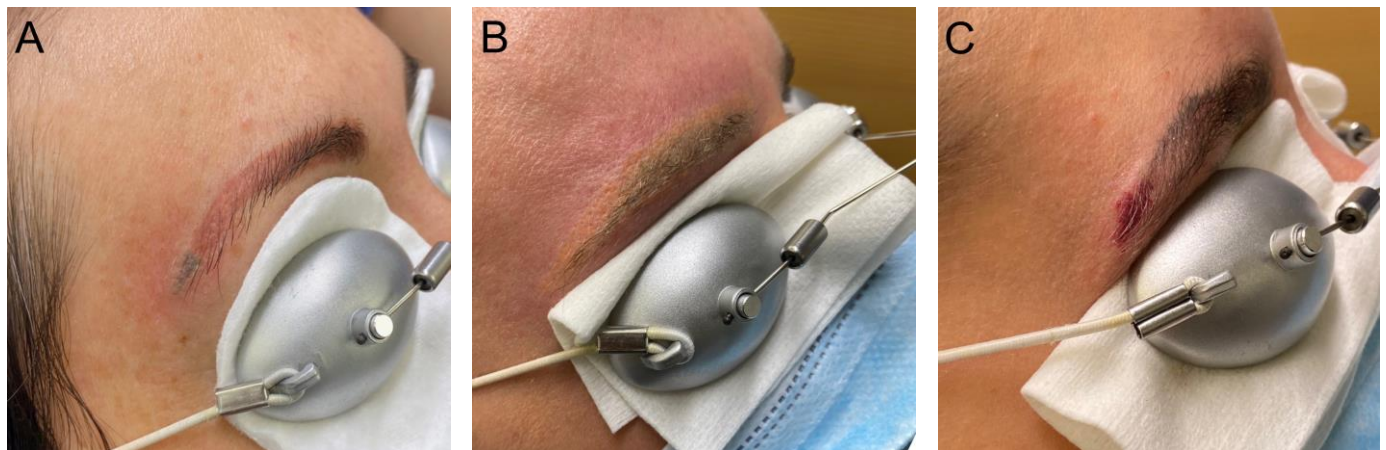


Figure 3. Typical immediate reactions after laser shot: (A) Grey discoloration of an orange pigment; (B) Mild and localized erythema; (C) Bruise was a rare side effect.

Statistical analyses were performed in order to assess the impact of the patient's objective, the skin phototype, and the occurrence of warm pigments in the cosmetic tattoos on the number of laser sessions. Table 3 summarizes the results of ANOVA. The required number of laser sessions was significantly lower when the objective was to correct cosmetic eyebrow tattoos (1.92 sessions). More sessions were needed for total removal (3.40 sessions) or when creating a new cosmetic tattoo (3.24 sessions) was the patient's objective. Patients' phototypes (I to IV) had no significant influence on the number of required sessions. The statistical analysis was not performed on the patients with Fitzpatrick phototypes V and VI due to their weak numbers (respectively, 3 and 1). When warm pigments were present, the treatment required significantly more sessions (3.57 vs. 2.25, respectively). Examples of our results are shown in Figure 4.

Table 3. Results of ANOVA with *p*-value.

Groups	Average Number of Sessions (Min-Max)	Statistical Group ***	<i>p</i> Value
Objectives:			
Correct	1.92 (1–4)	B	0.02 *
Redo	3.24 (1–7)	A	
Remove	3.40 (1–8)	A	
Phototype:			
I	3.20 (2–5)		0.77
II	2.87 (1–6)		
III	3.31 (1–8)		
IV	2.77 (1–5)		
Warm pigments **: Visible	3.57 (1–8)	A	0.001 *
Not visible	2.25 (1–5)	B	
Discoloration of pigments during laser session:			
No color change	3.00 (1–8)		0.71
Darkening	2.88 (1–5)		
Age of last touch-up:			
<3 months	3.23 (1–6)		0.23
3–12 months	2.72 (1–5)		

Table 3. Cont.

Groups	Average Number of Sessions (Min-Max)	Statistical Group ***	p Value
1–4 years	3.48 (1–8)		
>4 years	2.56 (1–6)		

* means significant statistical differences when p value < 0.05 ; ** red, orange, and yellow pigments; *** when $p < 0.05$, the statistical groups were indicated (subjects from different statistical groups showed significant differences in terms of average number of laser sessions. For example, patients who wanted to correct their cosmetic tattoos required a lower number of laser sessions (group B) than patients who wanted to redo and remove their PMU (group A).

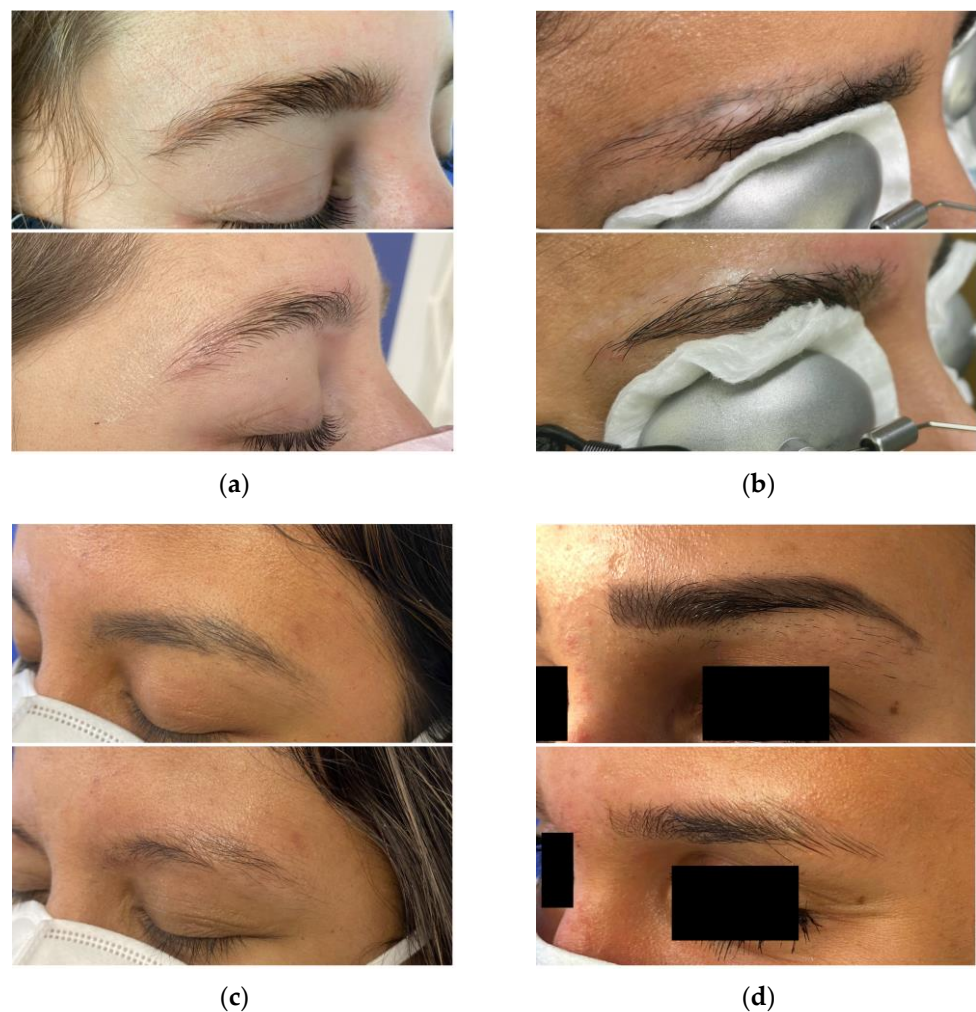


Figure 4. Removal of cosmetic eyebrow tattoos with picosecond laser: (a) Aged orange tattoo removed in 3 sessions; (b) The patient shows hypopigmentation issues after acid-based treatments. The remaining black pigment was removed in 3 laser sessions; (c) black tattoo removed in only one session; (d) eyebrow tattoo with black and red pigments removed in 6 sessions.

4. Discussion

This retrospective study included patients ranging in age from 21 to 71 years with Fitzpatrick phototypes ranging from I to VI. The distribution of phototypes was representative of Switzerland [24]. Most patients were women aged from 26 to 35 years, which corresponds to the group of active women who are present on social media and looking for time-saving ways to look their best throughout the day. A total of 70 out of 98 patients finished the full treatment, which represents a 71.42% engagement rate. Moreover, 16% of patients did not provide any follow up, so we did not know if the treatment was fully

completed. The engagement rate was in line with our main category of patients, PMU Enthusiasts who wanted to attenuate their current cosmetic tattoos to redo a new one.

Laser sessions were successfully performed with 755/532 nm picosecond lasers. The wavelength of 532 nm selected when red, orange, or yellow pigments did not respond at 755 nm (no clinical endpoint observed during laser shots) was required for 34% of patients. This wavelength was exclusively used with patients of phototypes I to IV. Only four patients with high skin phototypes (V, VI) were treated using PS 755 nm laser in order to fade their black cosmetic tattoo (Type I PMU-E). Hyperpigmentation trouble was observed for one patient with phototype V, confirming the high probability of adverse effects for this skin phototype. Generally, an average of three laser sessions was required to achieve patient objectives which are in line with previous work reported by Moustafa et al. (75% to 100% clearance of four brown and black eyebrow tattoos after 1 to 3 sessions using 1064/532 nm picosecond laser) and Hartman et al. (an average number of 3 sessions to obtain satisfactory results of cosmetic tattoo removal) [10,23]. The removal of cosmetic tattoos was achieved in 5 to 7 treatments with Q-Switched lasers, which confirms the efficacy of picosecond lasers [15,16].

As Table 3 shows, the occurrence of warm pigments was found to be the most significant parameter influencing the number of sessions. Among the 70 patients who completed their treatment, visible orange, red, and yellow pigments were found in 42 eyebrow cosmetic tattoos, which is in line with the fact that cosmetic tattoo ink is generally a mixture of several pigments to obtain a large set of shadows. The reactivity of each pigment that composes the cosmetic ink is dependent on its chemical nature and particle size [25,26]. This difference in reactivity might be responsible for the color change of eyebrow tattoos between sessions. This was typically observed with Phibrows inks containing black (CI77266, black carbon), orange (CI561170), and yellow (CI11767) pigments (Figure 5) [27]. The black pigment was eliminated during the first laser session leading to an orange tattoo. The second session removed the orange pigment leading to a yellow eyebrow. The yellow pigment was the most resistant and was removed in three sessions.

Cosmetic tattoo inks may include mineral iron oxides (red, yellow, and black pigments) that induce color change color. In this current study, 18 patients experienced immediate grey discoloration after laser shots (Figure 3A). Interestingly, grey discoloration was not found to significantly influence the total number of laser sessions. The color change was previously reported during nanosecond (NS) Q-switched laser treatment of cosmetic eyebrow and lip tattoos [17,28,29]. A previous study showed that color change could also occur with picosecond laser due to the reduction in iron oxide Fe_2O_3 used as red and yellow pigments in cosmetic ink formulations (CI 77,491 and CI 77492) [26]. The darkening was attributed to the reduction of Fe_2O_3 (III) into black Fe(II) oxide [17,26,28]. The mechanism for this change has not yet been fully elucidated due to the complex environment and physiological factors, although the reaction might possibly be induced via laser light and the creation of a local reducing environment. No immediate color change was observed with organic warm pigments, as they cannot chemically undergo similar reduction reactions like mineral oxides. Working at 532 nm was found to be much more efficient for removing them than at 755 nm, especially for yellow pigments. However, laser treatment at this wavelength might not be suitable for high phototypes and could possibly lead to more adverse events.

Laser sessions were found to be less painful at 532 nm, probably due to shallower laser penetration at 532 nm compared to 755 nm. The healing process was generally longer with 532 nm laser treatment, with prolonged redness and scabs. Despite the longer recovery time, patients were very satisfied with the results at 532 nm on warm pigments, which meant recovery time was not a barrier to continuing treatment. No permanent adverse effects and no major complications were reported meaning that removing eyebrow tattoos with a picosecond laser is a safe and efficient method.

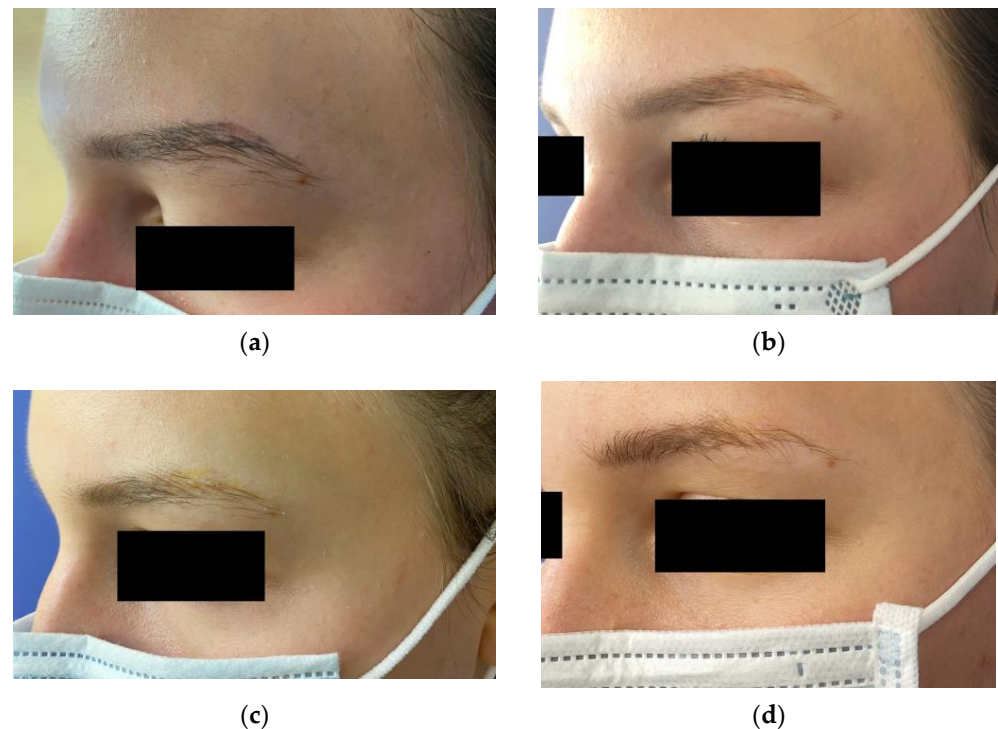


Figure 5. Removal of cosmetic eyebrow tattoos (only the tail) made with a Phibrows ink containing black carbon, orange, and yellow organic pigments: (a) before treatment; (b) after the first laser session, the black pigment was eliminated leading to an orange color; (c) after the second laser session, only the yellow pigment is remaining; (d) after 5 sessions.

5. Conclusions

This retrospective study on a large panel has shown that the picosecond laser was efficient in removing cosmetic tattoos composed of black and warm inks. Red, orange, and yellow pigments were more resistant than black ones and required more sessions for removal. Moreover, cosmetic tattoos may include multiple layers and diverse pigments, making it difficult to predict how the eyebrow tattoo will react during laser treatment. Hence, the removal of cosmetic tattoos requires a personalized procedure and information considering both patient and tattoo characteristics.

Further investigation is ongoing to assess optimal parameters for the removal of red and white pigments (not addressed in this current study). Our group of patients with skin phototypes V and VI was low, with 755/532 nm laser being not suitable. Laser removal of cosmetic eyebrow tattoos should be rather assessed with a 1064 nm picosecond laser.

Finally, data collected from this large panel allowed us to propose a patient classification with specific age, objective, and degree of engagement. Further research is required to strengthen this classification for the purpose of improving patient care and follow-up.

Author Contributions: C.M.-S. and S.S. contributed to the study conception and design. Material preparation, data collection, analysis, and interpretation were predominantly performed by C.M.-S. The first draft of the manuscript was written by C.M.-S. All authors have read and agreed to the published version of the manuscript.

Funding: This research received no external funding.

Institutional Review Board Statement: Not applicable.

Informed Consent Statement: Written informed consent was obtained from all subjects involved in this study.

Data Availability Statement: Data available on request due to restrictions eg privacy or ethical.

Conflicts of Interest: The authors declare no conflict of interest.

References

- Wetzel, C.L. Permanent cosmetics. *Plast. Surg. Nurs.* **2012**, *32*, 117–119. [\[CrossRef\]](#) [\[PubMed\]](#)
- Piccinini, P.; Contor, L.; Pakalin, S.; Raemaekers, T.; Senaldi, C. *Safety of Tattoos and Permanent Make-Up. State of Play and Trends in Tattoo Practices*; JRC Technical Report; EUR 27528; Publications Office of European Union: Luxembourg, Luxembourg, 2015; JRC96808; ISBN 978-92-79-52789-0.
- Dash, G.; Patil, A.; Kassir, M.; Goldman, M.P.; Gold, M.H.; Adatto, M.; Große-Büning, S.; Grabbe, S.; Goldust, M. Non-laser treatment for tattoo removal. *J. Cosmet. Dermatol.* **2023**, *22*, 74–78. [\[CrossRef\]](#) [\[PubMed\]](#)
- Kenani, Z.; Le Duff, F.; Hachem, J.P.; Le Pillouier-Prost, A.; Martin-Chico, R.; Patarin, M.; Laubach, H.; Ducamp, I.; Cante, V.; Perillat, Y.; et al. Scarring after chemical tattoo removal: A retrospective study. *Eur. J. Dermatol.* **2022**, *32*, 131–132. [\[PubMed\]](#)
- Hutton Carlsen, K.; Serup, J. Sequels to tattoo removal by caustic products. *Skin Res. Technol.* **2018**, *24*, 636–641. [\[CrossRef\]](#) [\[PubMed\]](#)
- Wollina, U. Depigmentation and hypertrophic scars after application of a fluid lactic acid tattoo eraser. *Wien. Med. Wochenschr.* **2015**, *165*, 195–198. [\[CrossRef\]](#)
- Leu, F.J.; Huang, C.L.; Wu, Y.S.; Wang, C.C. Comparison of picosecond versus nanosecond Nd:YAG lasers for the removal of cosmetic tattoos in an animal model. *Lasers Med. Sci.* **2022**, *37*, 1343–1350. [\[CrossRef\]](#)
- Gurnani, P.; Williams, N.; Al-Hetheli, G.; Chukwuma, O.; Roth, R.; Fajardo, F.; Nouri, K. Comparing the efficacy and safety of laser treatments in tattoo removal: A systematic review. *J. Am. Acad. Dermatol.* **2022**, *87*, 103–109. [\[CrossRef\]](#)
- McIlwee, B.E.; Alster, T.S. Treatment of Cosmetic Tattoos: A Review and Case Analysis. *Dermatol. Surg.* **2018**, *44*, 1565–1570. [\[CrossRef\]](#)
- Hartman, N.; Loyal, J.; Borsack, S.; Goldman, M.P.; Boen, M. Retrospective Review of the Laser Removal of Facial Cosmetic Tattoos. *Dermatol. Surg.* **2023**. online ahead of print. [\[CrossRef\]](#)
- Verhaeghe, E.; In De Cuyper, C.; Pérez-Cotapos, M.L. Techniques and devices used for tattoo removal. In *Dermatologic Complications with Body Art: Tattoos, Piercings and Permanent Make-Up*; Springer: Berlin/Heidelberg, Germany, 2010; pp. 91–105.
- Zhang, M.; Huang, Y.; Lin, T.; Wu, Q. Comparison of treatment with an Alexandrite picosecond laser and Nd:YAG nanosecond laser for removing blue-black Chinese eyeliner tattoos. *J. Cosmet. Laser Ther.* **2018**, *20*, 415–418. [\[CrossRef\]](#)
- Suchin, K.R.; Greenbaum, S.S. Successful treatment of a cosmetic tattoo using a combination of lasers. *Dermatol. Surg.* **2004**, *30*, 105–107. [\[PubMed\]](#)
- Fitzpatrick, R.E.; Lupton, J.R. Successful treatment of treatment-resistant laser-induced pigment darkening of a cosmetic tattoo. *Lasers Surg. Med.* **2000**, *27*, 358–361. [\[CrossRef\]](#) [\[PubMed\]](#)
- Moreno-Arias, G.; Camps-Fresneda, A. Use of the Q-Switched Alexandrite Laser (755 nm, 100 ns) for Eyebrow Tattoo Removal. *Lasers Surg. Med.* **1999**, *25*, 123–125. [\[CrossRef\]](#)
- Lee, C.N.; Bae, E.Y.; Park, J.G.; Lim, S.H. Permanent makeup removal using Q-switched Nd:YAG laser. *Clin. Exp. Dermatol.* **2009**, *34*, e594–e596. [\[CrossRef\]](#) [\[PubMed\]](#)
- Jimenez, G.; Weiss, E.; Spencer, J.M. Multiple Color Changes Following Laser Therapy of Cosmetic Tattoos. *J. Dermatol. Surg.* **2002**, *28*, 177–179.
- Cannarozzo, G.; Negosanti, F.; Sannino, M.; Santoli, M.; Bernardo, L.; Banzola, N.; Negosanti, L.; Nisticò, S.P. Q-switched Nd:YAG laser for cosmetic tattoo removal. *Dermatol. Ther.* **2019**, *32*, e13042. [\[CrossRef\]](#)
- Torbeck, R.; Schilling, L.; Khorasani, H.; Dover, A.K.; Saedi, N. Evolution of the Picosecond Laser A Review of Literature. *Dermatol. Surg.* **2019**, *45*, 183–194. [\[CrossRef\]](#)
- Wu, D.C.; Goldman, M.P.; Wat, H.; Chan, H.H.L. A Systematic Review of Picosecond Laser in Dermatology: Evidence and Recommendations. *Lasers Surg. Med.* **2021**, *53*, 9–49. [\[CrossRef\]](#)
- Hernandez, L.; Mohsin, N.; Frech, F.S.; Dreyfuss, I.; Vander Does, A.; Nouri, K. Laser tattoo removal: Laser principles and an updated guide for clinicians. *Lasers Med. Sci.* **2022**, *37*, 2581–2587. [\[CrossRef\]](#)
- Reiter, O.; Atzmony, L.; Akerman, L.; Levi, A.; Kershenovich, R.; Lapidot, M.; Mimouni, D. Picosecond lasers for tattoo removal: A systematic review. *Lasers Med. Sci.* **2016**, *31*, 1397–1405. [\[CrossRef\]](#)
- Moustafa, F.; Suggs, A.; Hamill, S.; Friedman, P. Successful Treatment of Cosmetic Eyebrow Tattoos in Fitzpatrick III–IV with Picosecond (1,064,532-nm) Neodymium-Doped Yttrium Aluminum Garnet Laser with a Perfluorodecalin-Infused Patch: A Pilot Study. *Lasers Surg. Med.* **2020**, *52*, 586–589. [\[CrossRef\]](#) [\[PubMed\]](#)
- Bataille, V.; Boniol, M.; De Vries, E.; Severi, G.; Brandberg, Y.; Sasieni, P.; Cuzick, J.; Eggermont, A.; Ringborg, U.; Grivegne, A.; et al. A multicentre epidemiological study on sunbed use and cutaneous melanoma in Europe. *Eur. J. Cancer* **2005**, *41*, 2141–2149. [\[CrossRef\]](#) [\[PubMed\]](#)
- Choi, M.S.; Seo, H.S.; Kim, J.G.; Choe, S.J.; Park, B.C.; Kim, M.H.; Seung, P.H. Effects of picosecond laser on the multi-colored tattoo removal using Hartley guinea pig: A preliminary study. *PLoS ONE* **2018**, *13*, e0203370. [\[CrossRef\]](#)
- Menozi-Smarrito, C.; Smarrito, S. Reactivity of cosmetic mineral pigments to picosecond laser. *J. Cosmet. Dermatol.* **2020**, *9*, 2667–2668. [\[CrossRef\]](#) [\[PubMed\]](#)
- MSDS Technical Data Sheet of Phibrows Pigments. Available online: <https://www.passion-for-beauty.com/material-information> (accessed on 27 March 2023).

28. Chung, W.K.; Yang, J.H.; Lee, D.W.; Chang, S.E.; Lee, M.W.; Choi, J.H.; Moon, K.C. Paradoxical darkening of unperceived tattoo ink after relatively low fluence from a Q-switched Nd:YAG (1064-nm) laser in the course of treatment for melasma. *Clin. Exp. Dermatol.* **2009**, *34*, e555–e557. [[CrossRef](#)]
29. Anderson, R.R.; Geronemus, R.; Kilmer, S.L.; Farinelli, W.; Fitzpatrick, R.E. Cosmetic tattoo ink darkening. A complication of Q-switched and pulsed-laser treatment. *Arch. Dermatol.* **1993**, *129*, 1010–1014. [[CrossRef](#)]

Disclaimer/Publisher’s Note: The statements, opinions and data contained in all publications are solely those of the individual author(s) and contributor(s) and not of MDPI and/or the editor(s). MDPI and/or the editor(s) disclaim responsibility for any injury to people or property resulting from any ideas, methods, instructions or products referred to in the content.